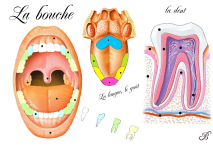
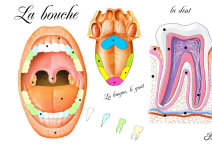


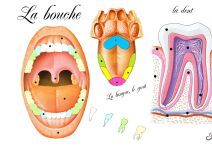
gencive



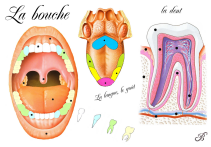
langue



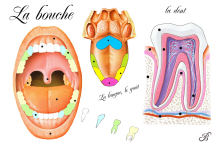
dentine



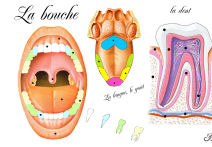
gencive



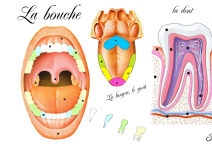
incisive



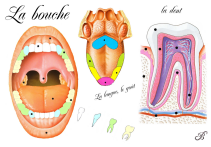
lèvre



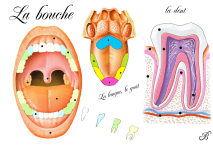
cément



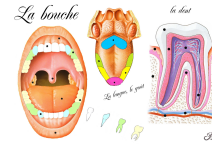
pulpe



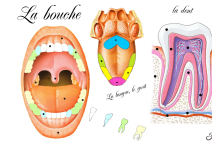
canine



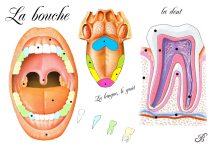
goût amer



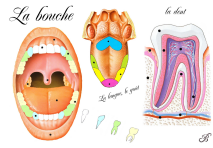
nerf



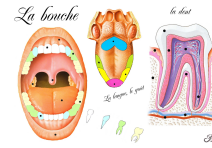
mâchoire



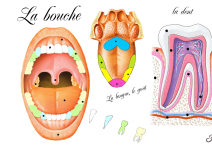
prémolaire



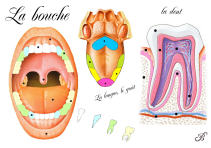
goût acide



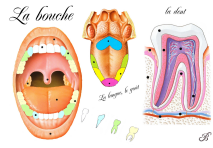
veinule



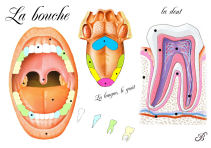
artériole



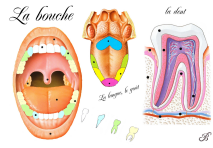
molaire



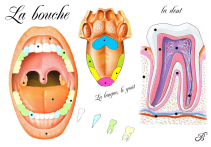
goût sucré



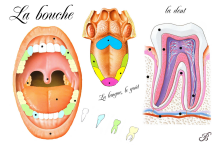
amygdale



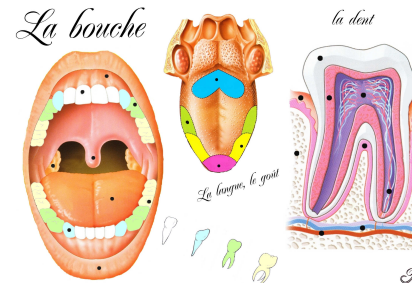
goût salé



luette

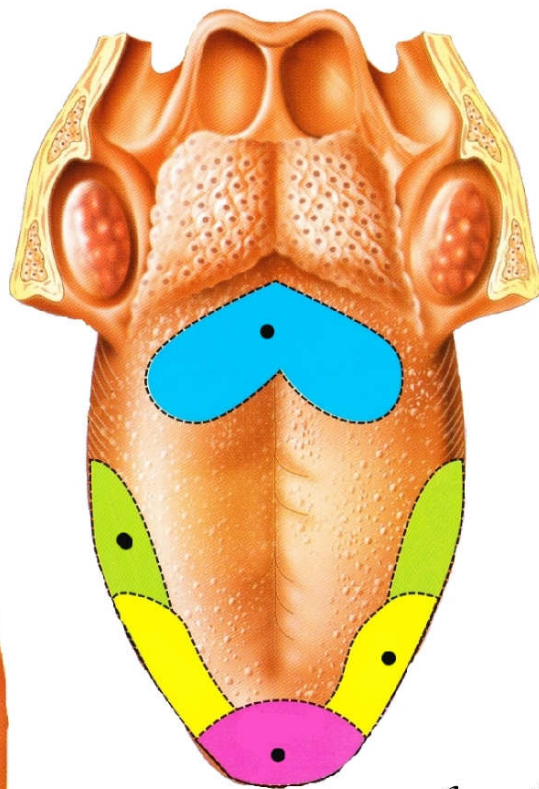
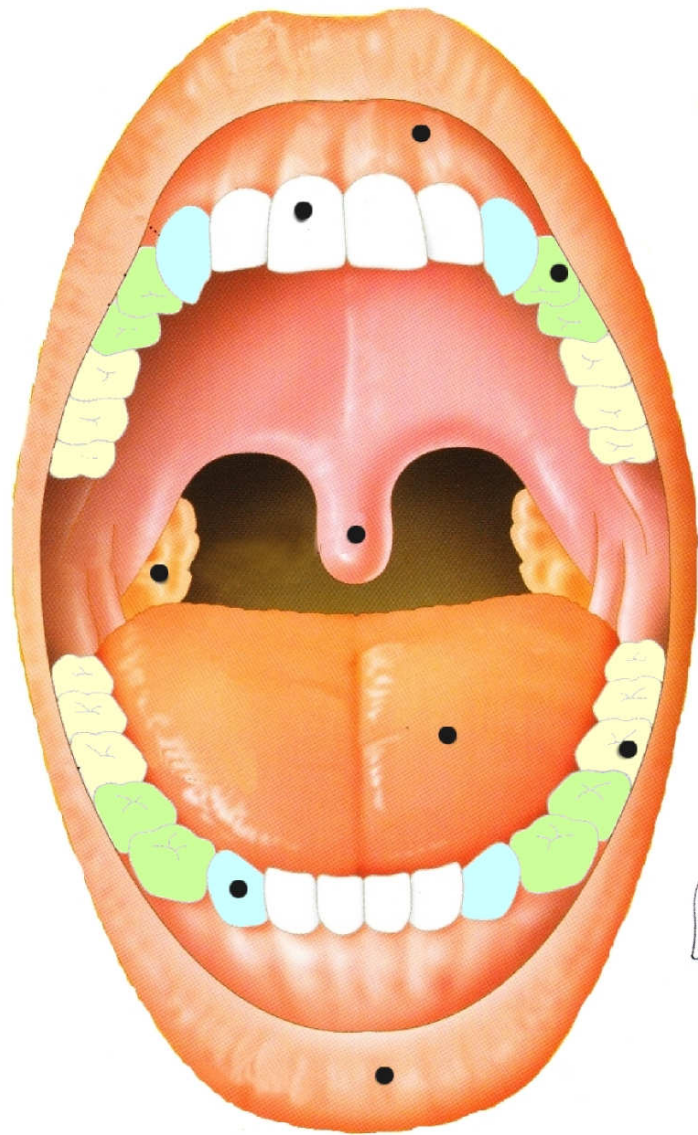


émail

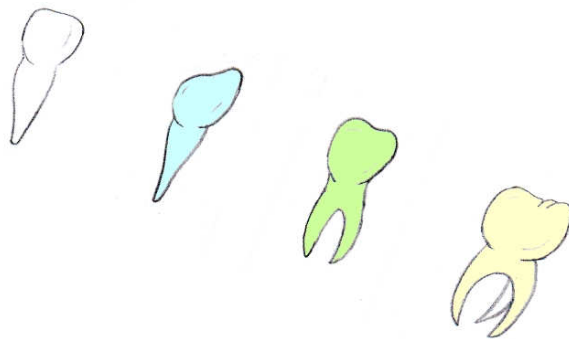


la bouche

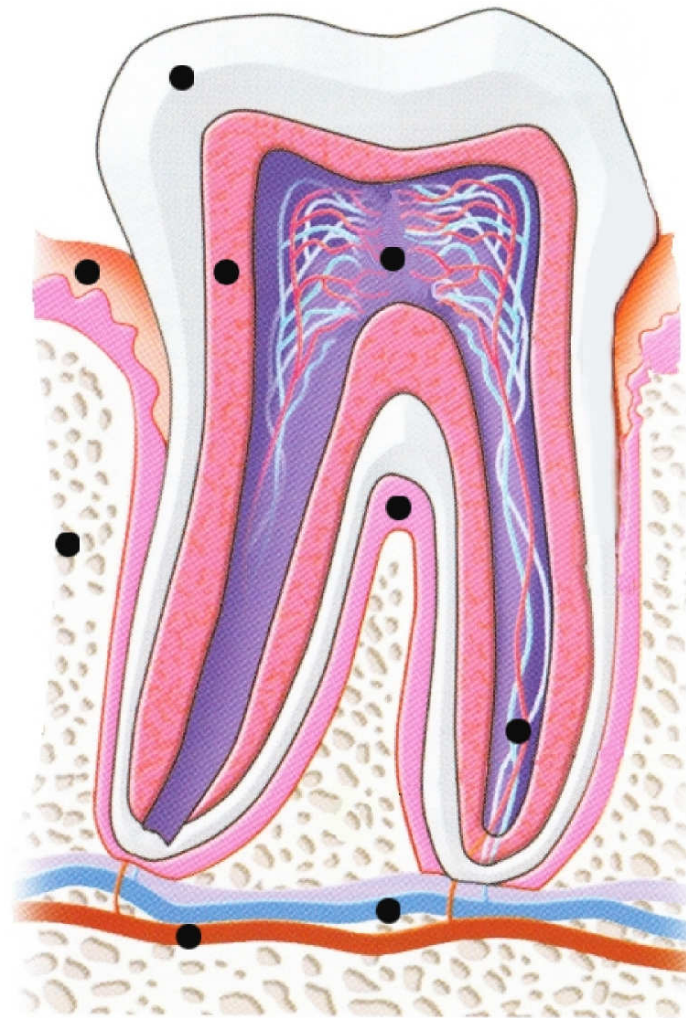
La bouche



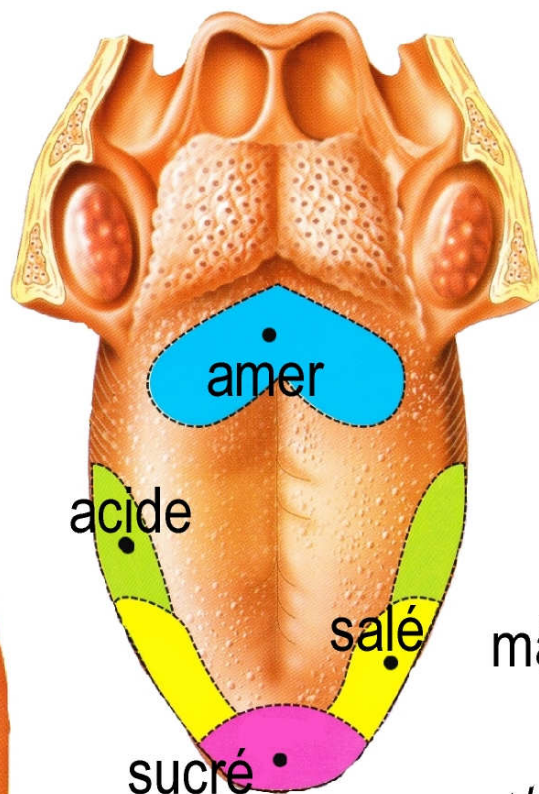
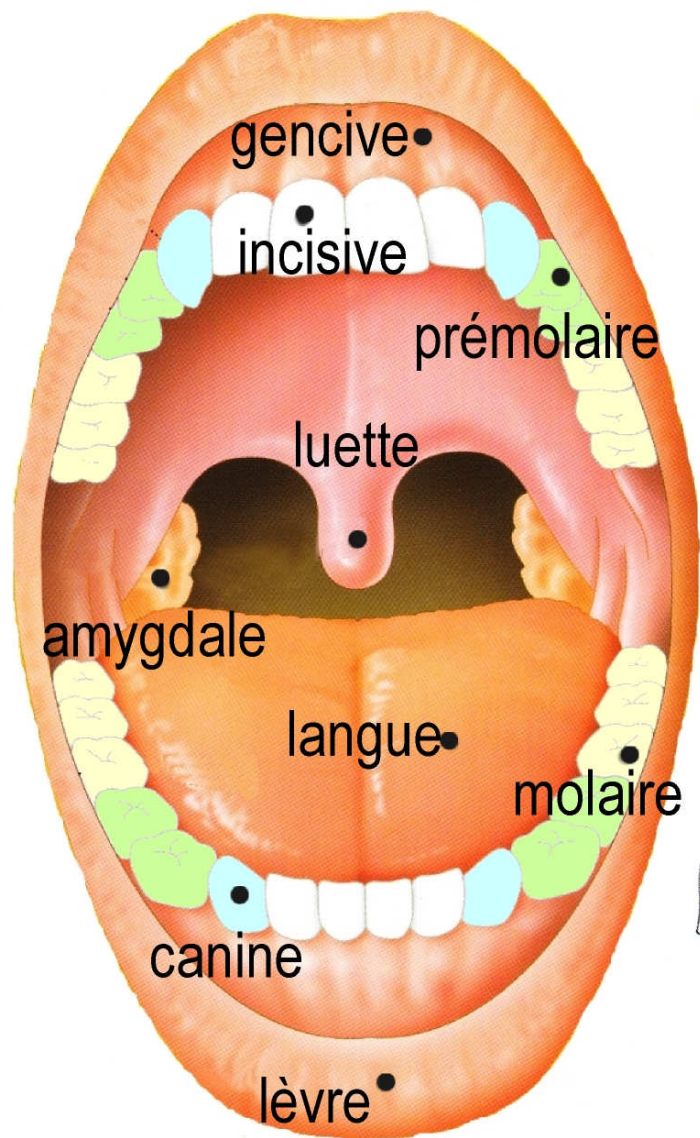
La langue, le goût



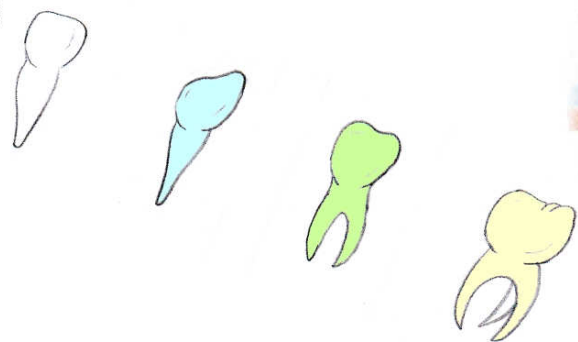
la dent



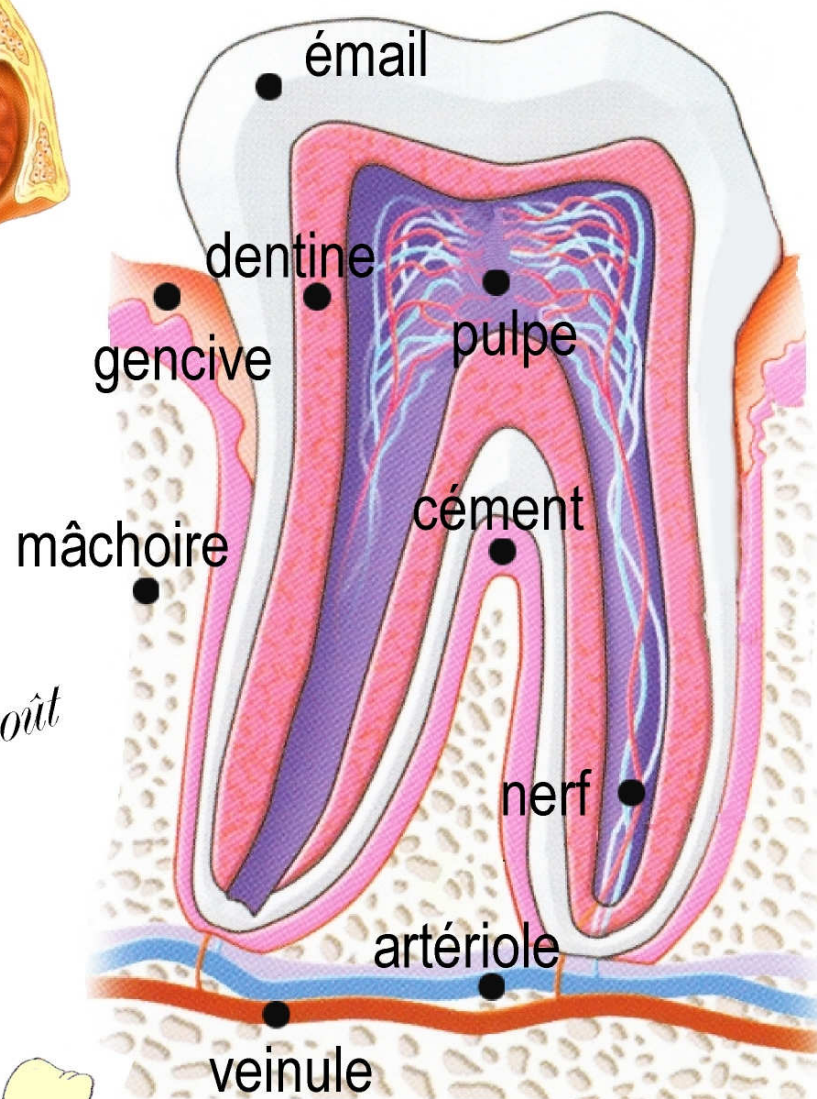
La bouche



La langue, le goût



la dent



B